

See discussions, stats, and author profiles for this publication at: <https://www.researchgate.net/publication/390364072>

# Using variations in cloacal disc regions to individually identify Congo caecilians *Herpele squalostoma* (Amphibia: Gymnophiona)

Article in *Herpetological Journal* · April 2025

DOI: 10.33256/35.2.110115

CITATIONS

0

READS

118

4 authors:



**Kimberley Carter**

Zoological Society of London

14 PUBLICATIONS 79 CITATIONS

SEE PROFILE



**David Gower**

Natural History Museum, London

417 PUBLICATIONS 11,734 CITATIONS

SEE PROFILE



**Mark Wilkinson**

Natural History Museum, London

413 PUBLICATIONS 19,146 CITATIONS

SEE PROFILE



**Benjamin Tapley**

ZSL

179 PUBLICATIONS 1,492 CITATIONS

SEE PROFILE

Published by the British  
Herpetological Society
<https://doi.org/10.33256/35.2.110115>

# Using variations in cloacal disc regions to individually identify Congo caecilians *Herpele squalostoma* (Amphibia: Gymnophiona)

Kimberley C. Carter<sup>1</sup>, David J. Gower<sup>2</sup>, Mark Wilkinson<sup>2</sup> & Benjamin Tapley<sup>1</sup>

<sup>1</sup>Zoological Society of London, Outer Circle, Regent's Park, London NW1 4RY, UK

<sup>2</sup>Herpetology Lab, Natural History Museum, London SW7 5BD, UK

Photographic identification and pattern-matching techniques are increasingly used for minimally invasive identification of individual amphibians. However, many caecilian species lack obvious, distinctive patterns or colourations (as well as limbs) which makes visual identification challenging. We used photographic records and Wild-ID to investigate the use of cloacal discs and surrounding annular grooves for individual identification in a captive population of *Herpele squalostoma* at ZSL London Zoo and compare similarity with preserved specimens. We photographed seven captive *H. squalostoma* over a maximum period of 59 months and 43 preserved museum specimens. We found that Wild-ID analysis of photographs is not viable for individual identification of this species. However, our results showed that the software could distinguish between animals, scoring >0 (0 = no match, 1 = perfect match) for photographs of the same live animal. However, the software did not reliably recognise individuals over time; where photographs were matched against the same animal from different dates the mean scores fell below the threshold of 0.1 (mean score of photographs with annular grooves present = 0.00397825; mean score of photographs of cloacal disc only = 0.0213814). When comparing a subset of all museum specimen photographs the similarity score was very low (mean = 0.00039712), however preservation quality and size differences may have confounded our results and made the scores unreliable. A photograph-matching survey performed by zoological and biological research professionals proved that *H. squalostoma* can be identified by direct inspection of photographs of the cloacal disc region (n = 82, mean = 60% correct, SD = 34%, median = 71%). Although Wild-ID is not a valid method for long-term identification based on the cloacal disc region, distinctive differences are visible to the eye and suitable for photographic identification in small, captive populations and thus may be beneficial to ex-situ populations of caecilians.

**Keywords:** amphibian, identification, pattern, photographic, non-invasive

## INTRODUCTION

The ability to individually identify animals is important both for captive management within zoological institutions, laboratories and in private care, and in field studies. Unique identification allows for the monitoring of population sizes, population dynamics and sex ratios in the field, the provision of individual needs, the recording of longevity and the individual life history of an animal such as veterinary history and reproduction in captive collections (e.g. Ashton, 1978; Donnelly et al., 1994; Silvy et al., 2005; Tapley et al., 2019).

Using photographic records of natural markings is minimally invasive and can often be performed quickly with little specialist equipment. Photographic identification (ID) has been used successfully to identify individual amphibians in all three extant amphibian orders (Arntzen et al., 2004; Bailey, 2004; Bradfield, 2004; Kenyon et al., 2009; Tapley et al., 2019; Årvarsson et al., 2022). Some amphibians, including many caecilians (order: Gymnophiona), lack obvious, distinguishing markings.

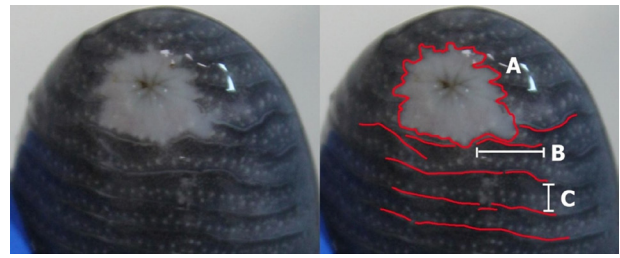
This potentially makes photographic identification challenging, although natural variations in annulation patterns in *Dermophis mexicanus* have been used to distinguish animals within a small, captive population (Wright & Minott, 1999) and the colour pattern of the head region in *Ichthyophis* cf. *kohtaoensis* has been used for distinguishing between individuals of this species in the field (Kramer et al., 2001) and in captivity (Kupfer et al., 2004). Although several different methods have been used to mark individual caecilians, including Panjet, freeze branding, visible implant elastomer tags and soft visible implant alphanumeric tags (Measey et al., 2001; 2003; Gower et al., 2006), the efficacy of all these different techniques for the long-term identification of individual caecilians has not been evaluated and/or clearly verified (Tapley et al., 2019). Visible implant elastomer (VIE) was unsuccessful for the long-term identification of captive *Herpele squalostoma* and was completely undetectable in *Microcaecilia unicolor* (Tapley et al., 2019). Additionally, VIE is now known to cause concerning inflammation to internal organs in anuran amphibians (Cabot et al., 2021).

**Correspondence:** Kimberley C. Carter ([kimberley.carter@zsl.org](mailto:kimberley.carter@zsl.org))

*Herpele squalostoma* was the first caecilian species described from mainland Africa (Stutchbury, 1836). It is oviparous, with extended parental care in which hatchlings feed upon the skin of their attending mother (Koute et al., 2012; 2013). *Herpele squalostoma* is a powerful burrower with a heavily ossified skull. It can be locally abundant in suitably moist environments throughout its extensive range in West and Central Africa and large numbers of this species has been imported into Europe for the pet trade. Here we investigate whether photographic records of the cloacal disc and nearby annular grooves can be used as a reliable, minimally invasive method of individually identifying captive *H. squalostoma* and whether the pattern recognition software Wild-ID (Bolger et al., 2012) can be used as an effective tool for individual identification in this species.

## MATERIALS & METHODS

The Zoological Society of London (ZSL) London Zoo maintains seven *H. squalostoma* of unknown sex as part of a collaborative project with the Natural History Museum's Herpetology Research Group. Two animals were acquired in 2008, four years old at time of acquisition (animals 2 and 3), two animals in 2014, 15 months old at acquisition (animals 1 and 4), and a final group of three in 2021, 12 months old at acquisition (animals 5–7). Animals ranged in total body lengths from 49.8–60.79 cm (as of 2 November 2022 and 12 October 2022 respectively), measured from photographs in ImageJ 1.51k software (Schneider et al., 2012); accessible at [github.com/imagej/ImageJ](https://github.com/imagej/ImageJ)). During routine substrate changes, occurring every 6 to 12 months (Carter et al., 2021), or more frequent health checks, photographs of each animal's cloacal disc and surrounding annular grooves were taken over a range of 59 months maximum (animal 4) to 2 months minimum (animal 5) with a range of 1–24 months between consecutive images. During substrate changes, animals were placed within 9L boxes (Really Useful boxes, Really Useful Products Ltd., UK) filled with tank substrate for 1–4 hours, then photographed and weighed, before being returned. In turn, animals were placed individually within transparent plastic bags, wet with warm tap water, so as not to desiccate the animal, and photographed using a Canon EOS 800D digital camera (Canon Inc., Tokyo, Japan) fitted with a Canon EF-S 18–55 mm f/3.5–5.6 IS lens. The animals were gently restrained, and the bags pulled taught over the cloacal disc to allow for a clear image with negligible impact from the plastic bag. However, in some cases, where animals proved difficult to restrain in a wet bag, photographs were taken of animals restrained instead in gloved hands. Photographs were taken of animals 1–4 from 4–6 substrate change or health check events, and of animals 5–7 from 2–3 events: upon completion of the quarantine period on 20 January 2022 and from subsequent individual health checks and substrate changes. The potentially unique and individual markers were identified and compared by eye; the most obvious characters being the outline shape of the disc region and the structure, spacing and relative positions of the adjacent annular grooves (Fig. 1).



**Figure 1.** Key characteristics used to identify individual *Herpele squalostoma*. The left image is unaltered for comparison. The right annotated image shows characteristics - **A.** the outline shape of the cloacal disc region, **B.** the extent and shape of the annular grooves and **C.** the proximity of adjacent annular grooves.

In addition to captive animals, the cloacal discs and adjacent annular grooves of 45 preserved specimens of *H. squalostoma* from the NHM's collection (see supplementary material) were photographed using a DSLR camera (Canon EOS 800D). Preserved specimens varied in size and condition. Extremely desiccated or dissected specimens were excluded from the final sample size of 43.

We use the term “cloacal disc” to refer to the more or less differentiated region that immediately surrounds the vent (the external opening of the cloaca). This subcircular disc is typically paler than the adjacent body, and it lacks annular grooves.

### Wild-ID methods

Photographs of the captive animals at ZSL were cropped to produce two sets of images for Wild-ID pattern-recognition software (Bolger et al., 2012; accessible at <https://faculty-directory.dartmouth.edu/douglas-thomas-bolger>). The software uses a scale invariant feature transform operator (SIFT), which extracts distinctive features from images and automatically corrects for skewed scale, distortion or rotation (Lowe, 2004). The software matches all the images and generates a similarity score where 1 = a perfect match and a score of 0 = no similarity at all (Bolger et al., 2012). A score of 0.1 has been recommended as an arbitrary threshold for a successful match by Bendik et al. (2013).

Image set 1 had the majority of the background cropped and the body of the caecilian cropped to nine annuli (rings) anterior to the cloaca disc, except in some instances where gloves or equipment obscured this, and the image was cropped closer to the disc. Image set 2 was cropped to show only the cloacal disc. All NHM specimen photographs were cropped from nine annuli anterior to the cloacal disc. Wild-ID was used to compare all cropped images for the animals at ZSL against themselves over all available dates, and with all other captive animals across all dates, and for the NHM specimens against all other NHM specimens.

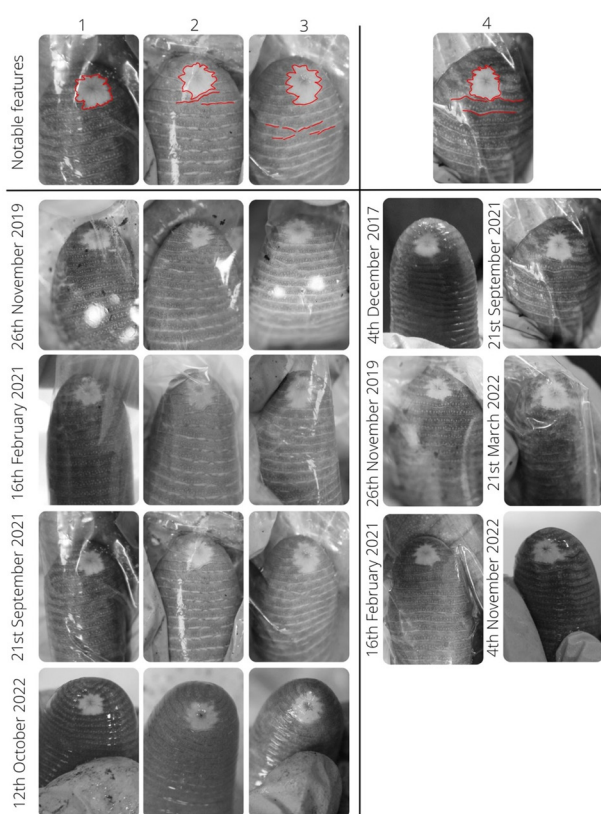
### Survey

A photo-matching survey was created in Survey Monkey (Accessible at <https://www.surveymonkey.co.uk/r/J3F8R28>). Survey participants were provided with seven multiple choice questions and asked to match separate

images of each study animal from small image pools of seven potential candidate matches, containing one of the same animal from a different date and one of each other animal. All images were randomly selected, however, some duplication of images between questions was unavoidable due to the limited bank of images for some animals. Answer images were the same for each participant, but the display order was randomised. The survey was advertised via social media and internal communication predominantly targeted towards animal care, veterinary and biological research professionals, and was open from 9 June 2013 to 15 July 2023. All responses were anonymous.

## RESULTS

All seven captive animals have distinct cloacal discs and adjacent annular grooves, which can be seen by eye (Figs. 2 & 3).

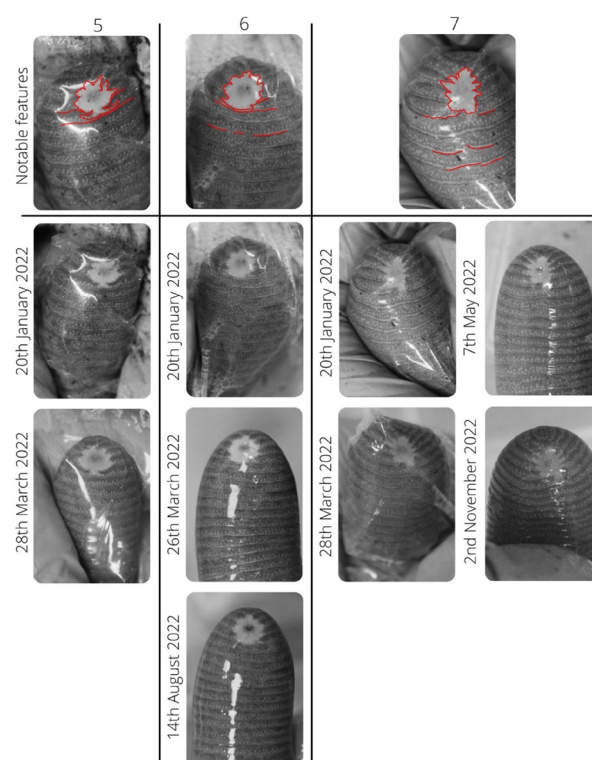


**Figure 2.** Photographs of the ventral view of the body terminus of the four largest study specimens of *Herpele squalostoma*, cropped to display the cloacal disc and approximately nine preceding annuli. The notable characteristics of each individual are outlined in red on the top reference images, alongside dated comparison pictures for study animals 1 to 4. Photographs range across 59 months for animal 4 (4 December 2017–4 November 2022) and 34.5 months for animals 1 to 3 (26 November 2019–12 October 2022). Notable features consist of the shape of the disc and position of the adjacent annular grooves.

## Wild-ID results

Comparing original images to themselves returned only perfect scores, indicating that the software performed appropriately. Photographs of captive animals were compared against all other photographs and did not match any other animal, suggesting Wild-ID can distinguish individual *H. squalostoma* based on the cloacal disc region. Photographs with annuli present for individual captive *H. squalostoma* were compared against themselves from all other available dates and scored very poorly (range = 0.000001–0.038003; mean = 0.00397825; SD = 0.008952253). This was repeated for cropped photos where only the cloacal disc was present and produced higher but still relatively low scores (range = 0.000001–0.104389; mean = 0.0213814; SD = 0.03).

Wild-ID scores for the 43 NHM museum specimens indicated very little similarity between individual specimens. In general, there was similarity between all but three specimens, which did not match any others. Overall similarity scores were very low (range =



**Figure 3.** Photographs of the ventral view of the body terminus of the three smallest study specimens of *Herpele squalostoma*, cropped to display the cloacal disc and approximately nine preceding annuli. The notable characteristics of each individual are outlined in red on the top reference images, alongside dated comparison pictures for study animals 5 to 7. Photographs range across 2 months for animal 5 (20 January 2022–28 March 2022), <7 months for animal 6 (20 January 2022–14 August 2022) and <10 months for animal 7 (20 January 2022–2 November 2022). Notable features consist of the shape of the disc and position of the adjacent annular grooves.

**Table 1.** Survey results for the seven study *Herpele squalostoma* in order of relative difficulty (1 = most difficult, 7 = least difficult), and the mean scores and SD. Comment section includes any notable reasons for the relative difficult scores such as shine present in photograph used in survey.

Difficulty	Animal	Mean score	SD	Comments
1	2	0.4 (38%)	0.49	Cloacal disc is slightly more elongated in correct answer photograph compared to question photograph No obfuscations
2	1	0.5 (52%)	0.5	Shine around cloacal disc on one answer photograph (34% of participants selected) compared to correct answer (43% of participants selected)
3	4	0.5 (54%)	0.5	Shine around cloacal disc on one answer photograph (29% of participants selected) compared to correct answer (54% of participants selected)
4	3	0.6 (60%)	0.49	Shine obscuring bottom of cloacal disc region in question photograph
5	7	0.7 (67%)	0.47	No obfuscations
6	5	0.7 (74%)	0.44	No obfuscations
7	6	0.8 (75%)	0.43	No obfuscations

0–0.0215; mean = 0.00039712; SD = 0.0013514). Both captive and museum specimens scored well below the recommended threshold of 0.1 for a match (Bendik et al., 2013; Åvarsson et al., 2022).

### Survey results

Of a total of 82 responses, the mean score equalled 4.2/7 pts (60%), SD = 2.38 pts (34%), median = 5 pt (71%) range = 0–7 pts (0–100%). Questions were scored on relative difficulty as produced by Survey Monkey analytics with animal 2 being the most difficult to correctly identify and animal 6 the least difficult (Table 1).

## DISCUSSION

Wild-ID assessment of photographs of the cloacal disc and surrounding region does not appear to be a viable, reliable method of individual identification for *H. squalostoma*. The similarity results do indicate that cloacal discs are distinctive with little similarity between individuals in both the live population and preserved specimens. The captive population animals only matched with themselves and mean results for the preserved specimens were well below the recommended threshold of 0.1 for similarity

(Bendik et al., 2013; Åvarsson et al., 2022). This may support the individuality of cloacal region appearances, but the low similarity score may also have been a result of the varying preservation condition and size differences of the preserved specimens.

Despite the apparent uniqueness of individuals, Wild-ID cannot be used to identify animals over time; comparisons between photographs of the same live individuals over time (with little change in cloacal disc shape seen by eye), also scored well below the 0.1 threshold. This may be explained by the limited and basic nature of the identifiers, unlike more ornate or varied patterns typically used for Wild-ID identification in other amphibians (Crawford-Ash & Rowley, 2021, Åvarsson et al., 2022), and/or due to interference of reflections, plastic bag textures and other obfuscations, as suggested by an increased score when comparing only the cloacal disc. Because the software perfectly matches duplicate images, it is unlikely that the confounding effects are due to software power alone and may be predominantly due to image quality. Survey results support this with the highest difficulty questions being the ones with the most visible interference from shine. Questions where answer photographs had shine present also proved more difficult than when the question photograph had shine present. The highest difficulty question photograph had no major obfuscations present but there was noticeable change in the cloacal disc shape between the question and the correct answer photograph. This change in shape was a natural change over time, rather than a mechanical distortion during restraint for the photograph. The cause of the change is unknown but may be the result of an injury or due to changes in body shape due to growth. Survey questions were randomly selected from a pool of photographs, so the time between photographs and consequent changes in the shapes of characteristic could be more extreme than in a real world setting with frequent and consecutive photographs. Additional work is needed on fine-tuning photography methods to produce more standardised, better-quality images (e.g. Bradfield, 2004) that remove the impact of the obfuscations when using Wild-ID. This species poses difficulties with restraint, leading to the use of plastic bags for restraint and the production of low-resolution images. In addition, the caecilian's skin needs to be maintained damp, leading to shine. Therefore, better restraint and photography methods need to be developed before this study is to be repeated. Additionally, a study on the influence of image quality on the usefulness of Wild-ID may be undertaken to determine if Wild-ID can identify the same individuals with a range of image qualities. This would be particularly useful in field settings where image quality may vary greatly.

Despite the difficulties encountered using Wild-ID, captive individuals of *H. squalostoma* do show clearly recognisable differences in the appearance of the cloacal discs and surrounding annular grooves, visible to the human eye (Figs. 2 & 3), supported by the survey mean and median scores being above the percentage of random chance (14%). The distinguishing characters are generally stable and present, with only minor observable changes

across up to 59 months. The most notable changes in appearance over the course of the study were detected as small differences in the cloacal disc shape in animal 2 between November 2019 and February 2021, and in the thickness of annular grooves in animal 3 between 16 February 2021 and 21 September 2021. The cause of these changes is unknown, but one speculation is that visual changes could occur in relation to reproductive condition and season with the development of the glands that open on the edges of the annular grooves (Kuehnelt et al., 2012). The pattern of the folds that are present around the cloacal opening, were not used in this study as a distinguishable feature; more work is needed to determine if these folds are stable over time and if these could be used in addition to the features noted in both visual ID and by using pattern recognition software. Due to the relatively static appearance of the cloacal discs and surrounding annular grooves in photographs, direct observation of this region can be used as a reliable means to identify small numbers of adult *H. squalostoma*. We suspect that this method may not be viable for large numbers of specimens, where there are likely to be less distinctive features among individuals that would make individual identification more prone to human error.

One compounding issue with non-digital methods is human ability. The survey resulted in a wide range of scores (range = 0–100%; mean = 60%; SD = 34%; median = 71%). Because this survey was anonymous, to abide by human ethical restrictions, the knowledge background or the number of attempts by individuals is not known. It is possible with repeated exposure to the same animals and their key distinguishing features that scores might improve. This would be more advantageous in captive collections with repeated exposure to known individuals than in fieldwork settings.

More research needs to be carried out to determine the degree to which cloacal disc and adjacent annular grooves change over time that may impact long-term population monitoring; including if and at what age these characteristics become stable, or whether slight alterations occur throughout the animals' lifetimes. It is also unclear, as yet, whether the direct observation method works equally well for other caecilian species. All caecilian species have a cloacal disc, though with variation in how clearly it is differentiated (particularly in colour) from the surrounding region, and in some species annular grooves are present only anterior (and not adjacent or posterior) to the disc (e.g. Taylor, 1968). However, at least for *H. squalostoma*, for small, captive populations, where regular photographs are taken, this approach provides a minimally invasive method of identification that requires no additional equipment.

## ACKNOWLEDGEMENTS

We thank all members of the Herpetology team at ZSL London Zoo who assisted in the husbandry of the animals in this work; in addition to the authors, Daniel Kane, Joe Capon, Unnar Ævarsson and to Lewis Rowden for support in internal administration processes.

## Author contributions

Conceptualisation, K.C.C. and B.T.; methodology, K.C.C., M.W. and B.T.; formal analysis, K.C.C.; investigation, K.C.C.; data curation, K.C.C.; writing-original draft preparation, K.C.C.; writing-review and editing, D.J.G., K.C.C., B.T. and M.W.; supervision, B.T.; project administration, K.C.C. All authors have read and agreed to the published version of the manuscript.

## Data accessibility

Data used in this study can be acquired via correspondence author and are listed in supplementary material.

## REFERENCES

- Ævarsson, U.A.E., Graves, A., Carter, K.C., Doherty-Bone, T.M., Kane, D., Servini, F., Tapley, B. & Michaels, C.J. (2022). Individual identification of the Lake Oku clawed frog (*Xenopus longipes*) using a photographic identification technique. *Herpetological Conservation & Biology* 17(1), 67–75.
- Arntzen, J.W., Goudie, I.B.J., Halley, J. & Jehle, R. (2004). Cost comparison of marking techniques in long-term population studies: PIT-tags versus pattern maps. *Amphibia-Reptilia* 25(3), 305–315.
- Ashton, D.G. (1978). Marking zoo animals for identification. In: *Animal Marking*. Stonehouse, B. (Ed.). Palgrave: London. 24–34 p.
- Bailey, L.L. (2004). Evaluating elastomer marking and photo identification methods for terrestrial salamanders: marking effects and observer bias. *Herpetological Review* 35(1), 38.
- Bendik, N.F., Morrison, T.A., Gluesenkamp, A.G., Sanders, M.S. & O'Donnell, L.J. (2013). Computer-assisted photo identification outperforms visible implant elastomers in an endangered salamander, *Eurycea tonkawae*. *PloS ONE* 8(3), p.e59424.
- Bolger, D.T., Morrison, T.A., Vance, B., Lee, D. & Farid, H. (2012). A computer-assisted system for photographic mark-recapture analysis. *Methods in Ecology and Evolution* 3, 813–822.
- Bradfield, K.S. (2004). Photographic identification of individual Archey's frogs, *Leiopelma archeyi*, from natural markings. DOC Science Internal Series 191. Department of Conservation, Wellington, New Zealand, 36 p.
- Cabot, M.L., Troan, B.V., Ange-van Heugten, K., Schnellbacher, R.W., Smith, D., Ridgley, F. & Minter, L.J. (2021). Migration and histologic effects of visible implant elastomer (VIE) and passive integrated transponder (PIT) tags in the marine toad (*Rhinella marina*). *Animals* 11(11), 3255.
- Carter, K.C., Fieschi-Méric, L., Servini, F., Wilkinson, M., Gower, D.J., Tapley, B. & Michaels, C.J. (2021). Investigating the effect of disturbance on prey consumption in captive Congo caecilians *Herpele squalostoma*. *Journal of Zoological and Botanical Gardens* 2(4), 705–715.
- Crawford-Ash, J. & Rowley, J.J. (2021). Photo identification of individual Blue Mountains tree frogs (*Litoria citropa*). *Herpetology Notes* 14, 803–808.
- Donnelly, M.A., Guyer, C., Juterbock, E.J. & Alford, R.A. (1994). Techniques for marking amphibians. In: *Measuring and Monitoring Biological Diversity: Standard Methods for*



- Amphibians*. Heyer, W.R. (Ed.). Smithsonian Institution Press, Washington DC, USA: 277–284 p.
- Gower, D. J., Oommen, O.V. & Wilkinson, M. (2006). Marking amphibians with alpha numeric fluorescent tags - caecilians lead the way. *Herpetological Review* 37, 302.
- Kenyon, N., Phillott, A.D. & Alford, R.A. (2009). Evaluation of the photographic identification method (PIM) as a tool to identify adult *Litoria genimaculata* (Anura: Hylidae). *Herpetological Conservation and Biology* 4(3), 403–410.
- Kouete, M.T., Wilkinson, M. & Gower, D.J. (2012). First reproductive observations for *Herpele Peters*, 1880 (Amphibia: Gymnophiona: Herpelidae): evidence of extended parental care and maternal dermatophagy in *H. squalostoma* (Stutchbury, 1836). *International Scholarly Research Notices* 2012(1), 269690.
- Kouete, M.T., Ndeme, E.S. & Gower, D.J. (2013). Further observations of reproduction and confirmation of oviparity in *Herpele squalostoma* (Stutchbury, 1836) (Amphibia: Gymnophiona: Herpelidae). *Herpetology Notes* 6, 583–586.
- Kramer, A., Kupfer, A. & Himstedt, W. (2001). Haltung und Zucht der thailändischen Blindwühle *Ichthyophis kohtaoensis* (Amphibia: Gymnophiona: Ichthyophiidae). *Salamandra* 37, 1–10.
- Kuehnelt, S., Herzen, J., Kleinteich, T., Beckmann, F. & Kupfer, A. (2012). The female cloaca of an oviparous caecilian amphibian (Gymnophiona): functional and seasonal aspects. *Acta Zoologica* 93(2), 208–221.
- Kupfer, A., Kramer, A. & Himstedt, W. (2004). Sex-related growth patterns in a caecilian amphibian (genus *Ichthyophis*): evidence from laboratory data. *Journal of Zoology* 262, 173–178.
- Lowe, D.G. (2004). Distinctive image features from scale invariant keypoints. *International Journal of Computer Vision* 60, 91–110.
- Measey, G.J., Gower, D.J., Oommen, O.V. & Wilkinson, M. (2001). Permanent marking of a fossorial caecilian, *Gegeneophis ramaswamii* (Amphibia: Gymnophiona: Caeciliidae). *Journal of South Asian Natural History* 5, 141–147.
- Measey, G.J., Gower, D.J., Oommen, O.V. & Wilkinson, M. (2003). A mark–recapture study of the caecilian amphibian *Gegeneophis ramaswamii* (Amphibia: Gymnophiona: Caeciliidae) in southern India. *Journal of Zoology* 261(2), 129–133.
- Schneider, C.A., Rasband, W.S. & Eliceiri, K.W. (2012). NIH Image to ImageJ: 25 years of image analysis. *Nature Methods* 9(7), 671–675.
- Silvy, N.J., Lopez, R.R. & Peterson, M.J. (2005). Wildlife marking techniques. *Techniques for Wildlife Investigations and Management* 6, 339–376.
- Stutchbury, S. (1836). Description of a new species of the genus *Chameleon*. *Transactions of the Linnean Society, London* 17, 361–362.
- Tapley, B., Michaels, C.J., Gower, D.J. & Wilkinson, M. (2019). The use of visible implant elastomer to permanently identify caecilians (Amphibia: Gymnophiona). *The Herpetological Bulletin* 150, 18–22.
- Taylor, E.H. (1968). *The Caecilians of the World. A Taxonomic Review*. University of Kansas Press, Lawrence: U.S.A. 848 p.
- Wright, K.M. & Minott, T. (1999). Individual identification of captive Mexican caecilians (*Dermophis mexicanus*). *Herpetological Review* 30(1), 32–33.

Accepted: 1 October 2024

Please note that the Supplementary Material for this article is available online via the Herpetological Journal website: <https://thebhs.org/publications/the-herpetological-journal/volume-35-number-2-april-2025>